

## PERTINENT PEARLS ON ORTHOTIC ADJUSTMENTS AND CASTING

**G**iven the nuances of making adjustments to orthotic prescriptions, our expert panelists discuss their approaches in using adjustments such as first ray cutouts and metatarsal pads, and the tools necessary for making modifications. They also discuss which adjustments they will make themselves and which ones they will send out to an orthotics lab. Without further delay, here is what they had to say.

**Q:** How do you incorporate footwear when determining appropriate orthotic prescriptions?

**A:** Ideally, Howard Horowitz, DPM, says one should tailor the shoe and orthotic to the patient's pathology. For example, if the patient has hallux limitus, the

shoe should have a stiff sole with a lower heel. Dr. Horowitz does not make many orthotics for high-heeled shoes. Since an orthotic's primary function is controlling heel to toe gait, Dr. Horowitz says the benefit of an orthotic in a high-heeled shoe is questionable.

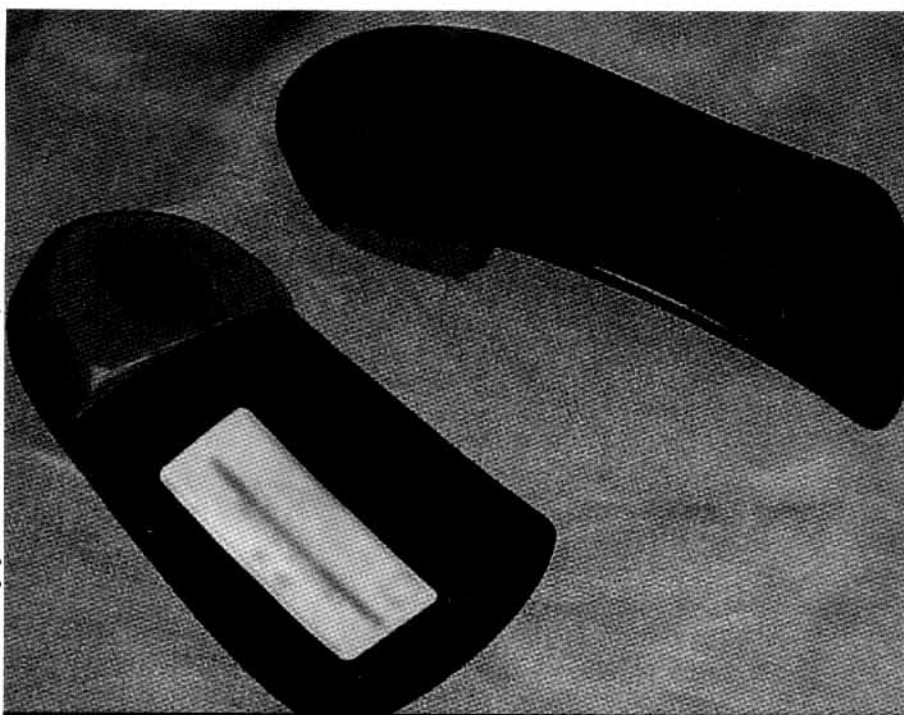
When prescribing an orthotic, DPMs must know the type of shoes the patient expects to wear, according to Douglas Milch, DPM. For a woman who wears a dress shoe, he prescribes a thinner graphite material and will probably leave out an extrinsic rearfoot post. Dr. Milch would use a narrow grind width and low heel cup height. Dr. Milch notes that shoes with a strong heel counter and sufficient depth can best house the orthotics and optimize functional results.

Dr. Horowitz prefers using an extrinsic rearfoot post in order to control the rearfoot as much as possible immediately after heel strike. With a dress flat or short dress heel, he will send both the shoe and cast to the orthotic lab for a better fit for the rearfoot post. Dr. Horowitz notes that grinding the thickness of the rear post to "almost a hole in the heel" will typically permit a successful fit for the device. Patients should always take orthotics to the store when purchasing new shoes, according to Dr. Horowitz.

"I try to impress on the patient the notion that while the orthotic supports and helps guide the foot, the shoe supports the foot over the orthotic," emphasizes Dr. Horowitz.

Bruce Williams, DPM, gives patients handouts on shoe suggestions. These handouts include one from Mark Reeves, DPM, and a handout from the American Academy of Podiatric Sports Medicine (AAPSM), which demonstrates how lacing techniques can aid in shoe fit. Dr. Williams will point out to patients the pros and cons of different shoes, and how orthotics will function better in shoes with motion control. Dr. Williams has recently started adding pedorthic modifications to shoes on a limited basis but notes that he sends most of those modifications, such as heel lifts on outsoles or rocker bottom soles, out to a pedorthist or the orthotic lab.

"If I had my way, everyone would be wearing a running shoe or an SAS walking shoe because most of the time when we prescribe orthotics, we are attempting to control foot motion," opines Dr. Milch. "You can make the greatest orthotic in the world. However, if patients either cannot fit it into



(Photo courtesy of Alona Kashani, DPM)

Here is a polypropylene functional foot orthosis with an EVA rearfoot post. Howard Horowitz, DPM, prefers using an extrinsic rearfoot post in order to help control the rearfoot as much as possible immediately after heel strike.

the shoe or put the orthotic in a flimsy shoe, the results are compromised at best.”

**Q:** What are the most common adjustments you make to orthotic devices?

**A:** Dr. Williams adds first ray cutouts of various sizes that often differ from the right foot to the left and also incorporates heel lifts and posts. He adds PPT™ (Langer) under the topcovers of cutouts. He uses first metatarsal grooves, a thinning of the orthotic shell or a trough in an ethylene vinyl acetate (EVA) device. In heel cups, Dr. Williams will add medial or lateral Kirby skives, utilizing 1/16, 1/8 or 1/4 inch of Korex or EVA if needed after construction of the device.

“There is little that can be done by a lab that persistent podiatrists cannot mimic themselves,” asserts Dr. Williams. “It may not always look as pretty but it will almost always function just the same.”

Dr. Horowitz has used an increased number of first metatarsal head and first ray cutouts to increase the proper function of the first ray. He usually calls on the lab to grind the extrinsic rearfoot post as thin as possible with little to no medial grind-off. Dr. Horowitz uses a heel cup as deep as the shoe permits. Generally, he uses minimal fill when fabricating a longitudinal arch so the device will fit the arch closely.

When Dr. Milch adjusts orthotic prescriptions, he commonly does so to increase the amount of desired control. For a patient with an extremely pronated foot, for whom an ankle foot orthotic (AFO) is inappropriate, he will use a medial heel skive, deeper heel cup height, wider grind, firmer material and rearfoot posting with a medial flange. He adjusts prescriptions according to the patient’s activity. For example, Dr. Milch will use a softer flexible material for a runner. For a patient with a leg length discrepancy of 1/4 inch or less, Dr. Milch will add that amount of discrepancy to the rearfoot post. For a discrepancy of more than 1/4 inch, he incorporates the additional lift into the midsole.

**Q:** Once orthotic devices are fabricated, what adjustments or modifications do you perform yourself and what type of adjustments do you return to the orthotic lab?

**A:** Drs. Horowitz and Milch both make use of grinders and heat guns. Dr. Horowitz notes the practicality of those tools, saying he can use a heat gun to lower an arch, grind off the medial distal rearfoot post or diminish rearfoot posting.

Dr. Horowitz also keeps topcover materials, metatarsal pads and rearfoot wedges in his in-office lab. He says they allow him to adjust orthotics more easily

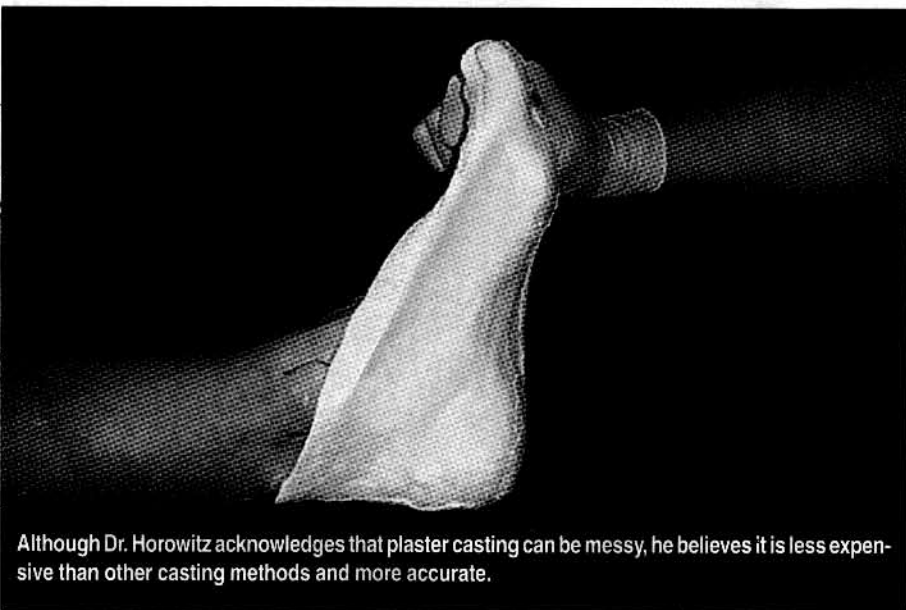
and enable him to have more control over the fabrication parameters that he orders from the lab. At times, Dr. Horowitz will have the orthotic lab leave a front extension unglued so he can place a metatarsal pad where he wants it when a patient presents for the dispensing of an orthotic. Dr. Horowitz formerly replaced top covers himself, especially when treating athletes, but he now sends them back to the lab since he found the process too time-consuming.

Like Dr. Horowitz, Dr. Milch uses a heat gun to lower arches. He will add Korex to the medial aspect of the rearfoot post and along the medial arch, which inverts the device, to gain more control. However, if an orthotic is too narrow, Dr. Milch will send it to the lab. If he makes three or more attempts at an adjustment and patients are still having trouble with the orthotic, Dr. Milch will send it back to the lab, noting that he and the orthotist can usually solve the problem. Dr. Milch notes that sometimes he will need to recast the patient and start over.

Dr. Williams does “99 percent” of orthotic adjustments himself, saying it is difficult for him to explain what he wants to someone over the phone. He keeps a sani-grinder in each of his two offices. He and his staff perform all topcover refurbishments and he will make all modifications of rearfoot posts for heel lifts, forefoot and rearfoot posting, and for first ray cutouts. If Dr. Williams has a serious problem with an AFO, he will return it to the lab but notes this is an isolated incident. Even if there is a problem with an AFO, Dr. Williams says one can use PPT and a heat gun to fix most problems.

“Personally, I think it makes you look bad if you cannot fix something in the office the same day or at least within a day or two,” says Dr. Williams. “Top cover replacements may take a week but they are a different story.”

**Q:** What is your opinion on plaster casting for orthotic devices? Do you always cast the same way or do you vary your approach depending upon the foot type? Do you scan the foot instead of using plaster?



Although Dr. Horowitz acknowledges that plaster casting can be messy, he believes it is less expensive than other casting methods and more accurate.

# Q & A Orthotics

**A:** All three panelists use plaster. Plaster casting works well for Dr. Milch, who usually uses suspension casting with the patient supine. If patients will not relax and instead fire their quadriceps and anterior tibialis muscles, he will use a prone casting technique. When fabricating accommodative devices, Dr. Milch marks lesions with a felt-tip marker and uses a semi-weightbearing technique.

As an alternative to plaster casting, Dr. Milch acknowledges the STS sock cast and scanning. In the end, he says what matters most is how one captures the foot position when the plaster sets.

Dr. Williams has used the CustomSelect Scanner (Amfit) for the past year. He says the product permits him to program everything he wants in a prescription and he can see it in 3D before the orthotic is produced. The scanner also lets Dr. Williams add heel lifts, medial or lateral heel skives, a first ray groove/trough or holes for plantarflexed metatarsals or plantar fibromas. The scanner lets him invert the device in varus or valgus, or only to the metatarsophalangeal joint.

Although he acknowledges that plaster casting can be messy, Dr. Horowitz believes it is less expensive than other casting methods and more accurate. He casts patients himself, noting that he tries to lock the midtarsal joint in the traditional manner of dorsiflexing the lateral rays. Lately, he has been paying more attention to capturing the lateral column accurately. Dr. Horowitz usually casts most if not all of a flexible forefoot varus.

Plaster works well if the technique is sound and can be repeated, according to Dr. Williams. He usually uses the same casting method, casting in a position that is slightly pronated from the subtarsal joint (STJ) neutral position. Dr. Williams says doing so facilitates a more comfortable patient fit and still has the same function. Dr. Williams will occasionally cast a patient in STJ neutral but only does so for those with severe flat feet and medially deviated STJ axes. Such an STJ neutral technique works well for some patients with AFOs and Richie braces but Dr. Williams advises DPMs not to overdo it since it may cause more problems than it solves. ■

*Dr. Horowitz is a member of the American Academy of Podiatric Sports Medicine. He is board certified by the American Board of Medical Specialties in Podiatry. He practices in Bowie, Md.*

*Dr. Milch is a member of the American Academy of Podiatric Sports Medicine. He is certified in podiatric orthopedics by the American Board of Podiatric Orthopedics and Primary Podiatric Medicine. He practices in Asheville, N.C.*

*Dr. Williams is a Fellow of the American College of Foot and Ankle Surgeons, and is board certified by the American Board of Podiatric Surgery. He is a member of the American Academy of Podiatric Sports Medicine. Dr. Williams practices in Merrillville, Ind.*

*Dr. Levine is in private practice and is also the director and owner of Physician's Footwear, an accredited pedorthic facility, in Frederick, Md.*